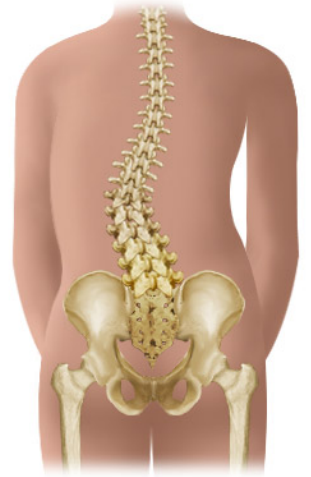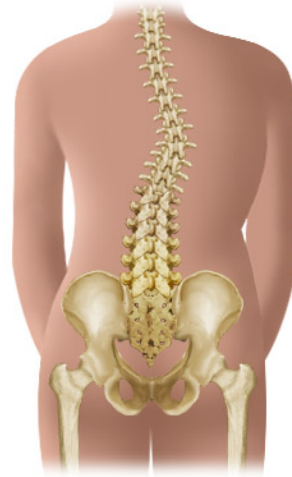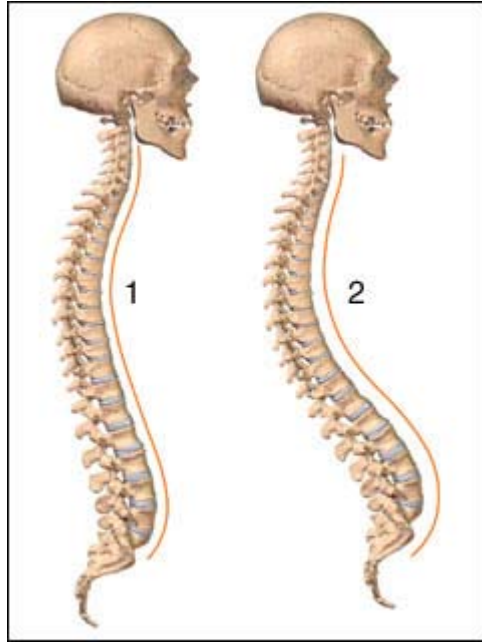
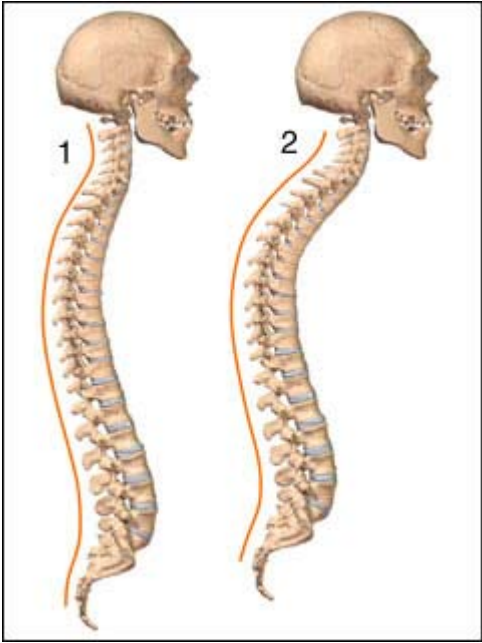
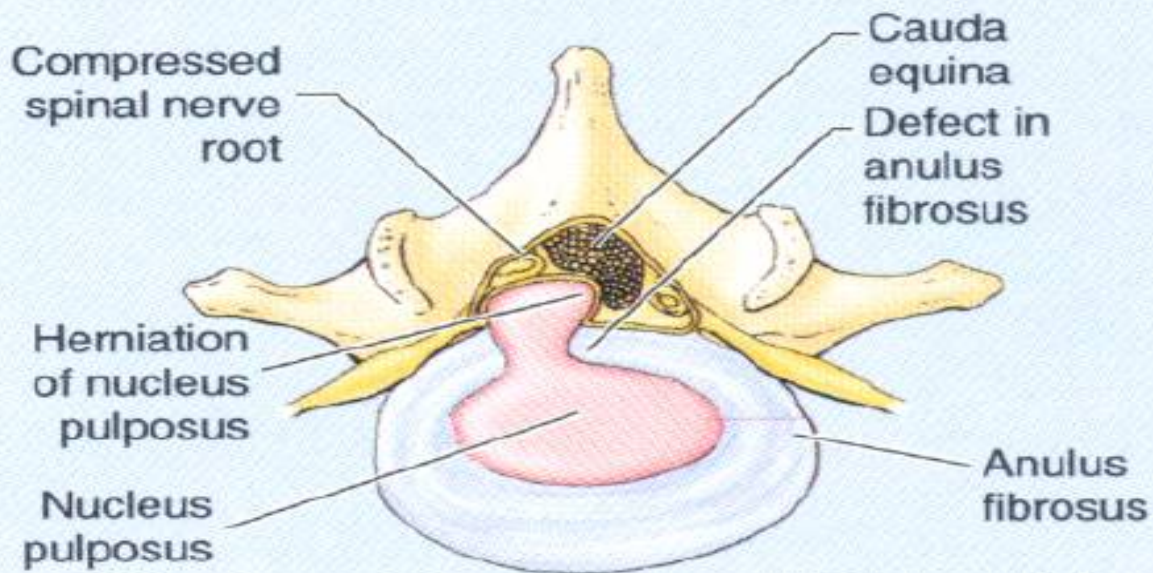
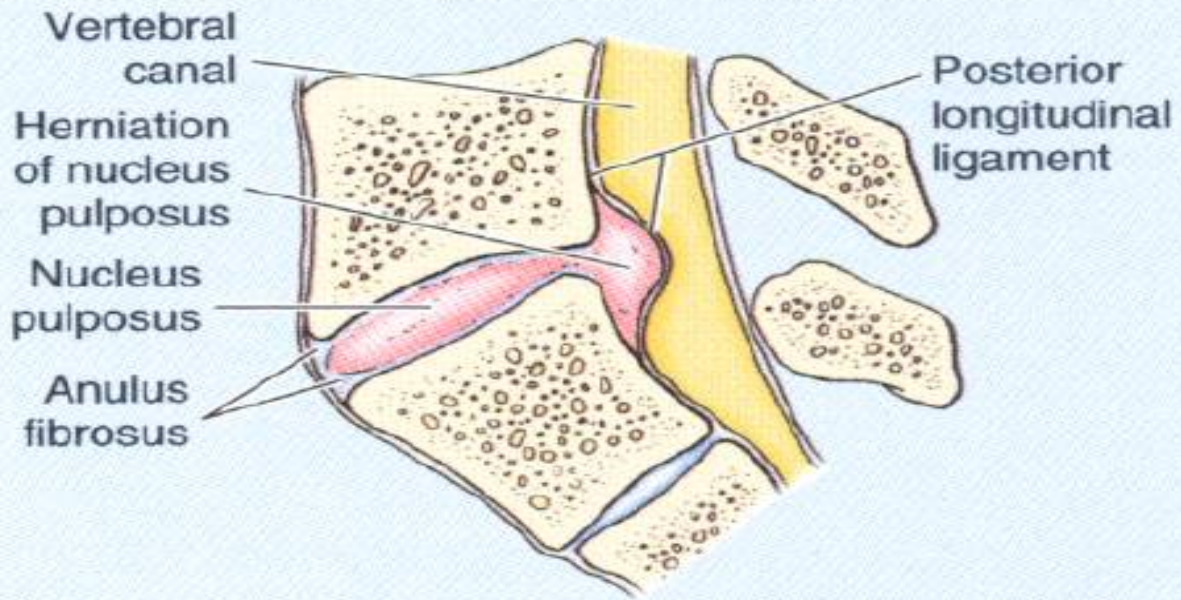


What's wrong here?

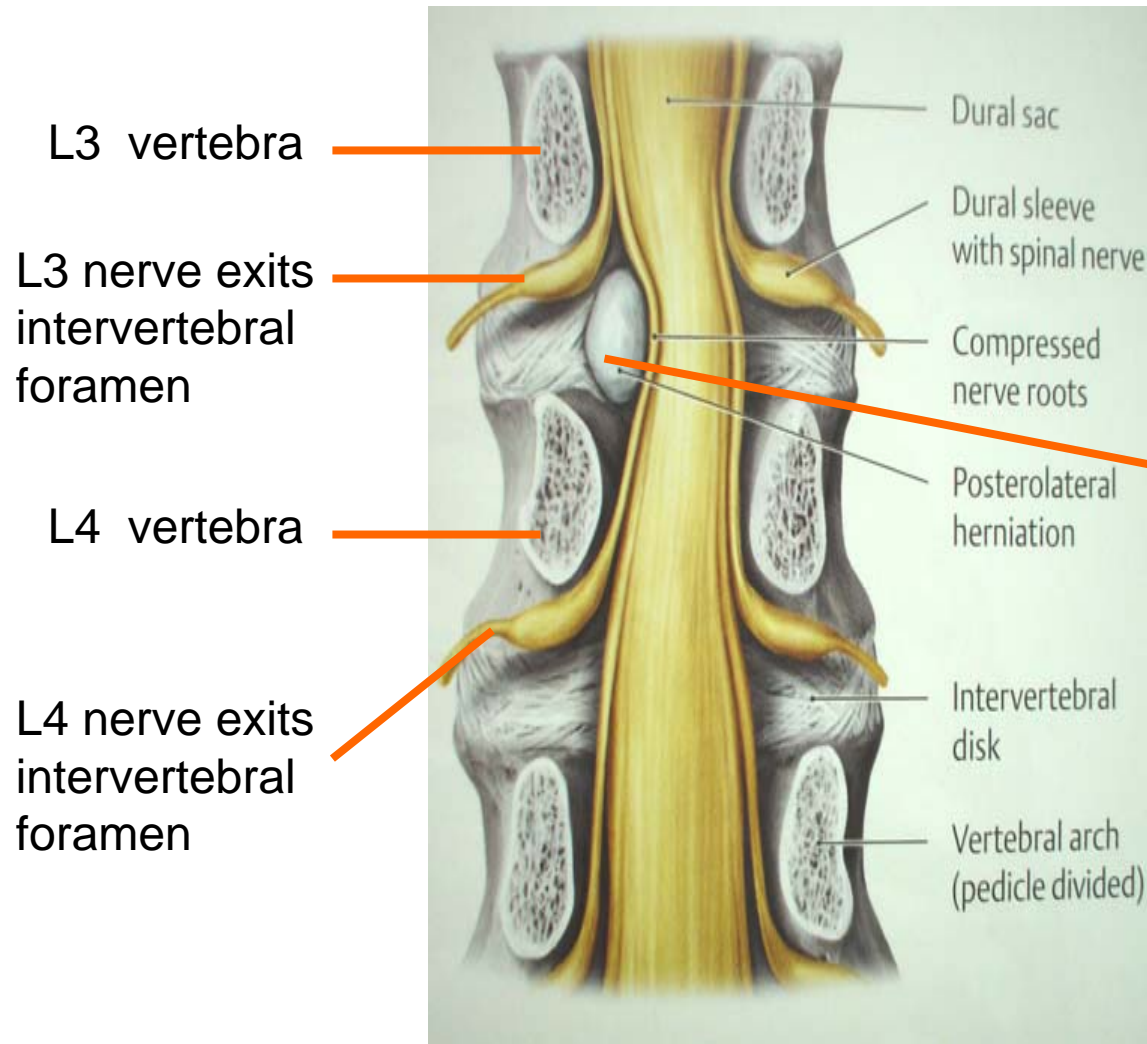
Science Olympiad

April 4, 2009

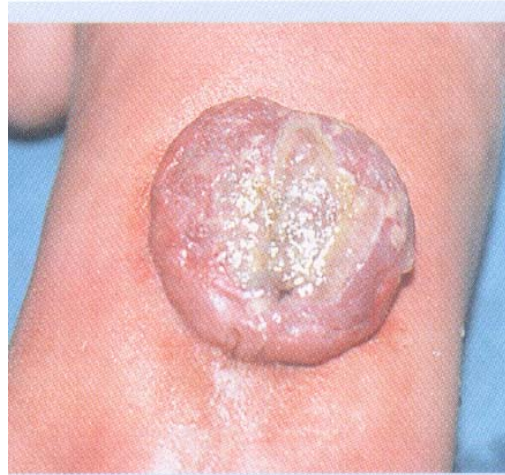
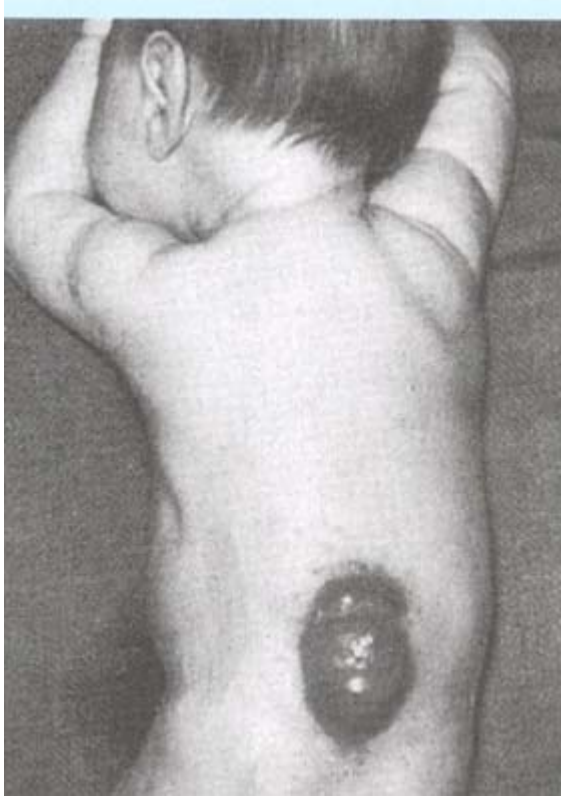


Posteriolateral herniation of intervertebral disc (nucleus pulposus) at L3 intervertebral foramen level.

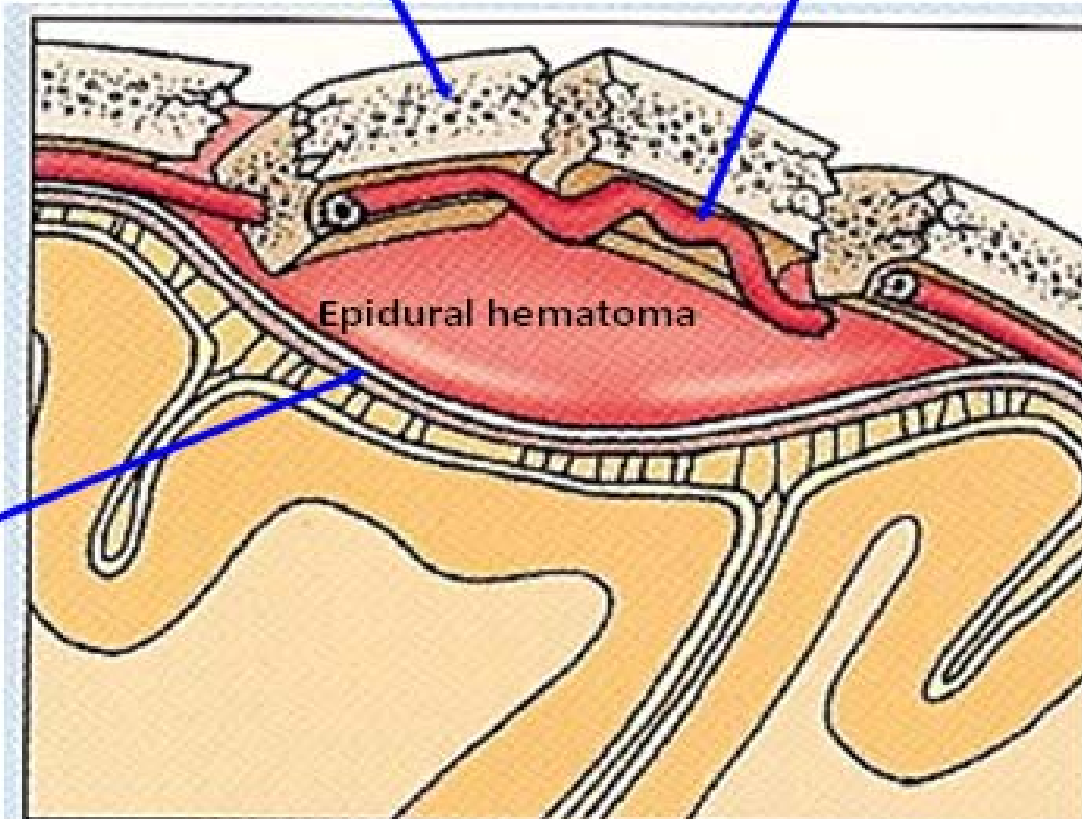


Disc Herniation at L3 intervertebral foramen compresses nerve fibers exiting at lower levels – L4 and L5 in this case.



Calvaria

Middle meningeal a.



Dura mater